EÜ Dişhek Fak Derg 2004; 25: 163-165

Neuropsyphilis Case: Neurological and Oral Findings

Nörosifiliz Olgusu: Nörolojik ve Oral Bulgular

Nesrin DÜNDAR[1] M. Cemal AKAY[2] Betül İLHAN[1] Esra AKAY[3]
Muhteşem GEDİZLİOĞLU[3] Sevtap GÜNBAY[2]

Ege Üniversitesi, Dişhekimliği Fakültesi, [1]Oral Diagnoz ve Radyoloji AD, [2]Ağız, Diş ve Çene Hastalıkları Cerrahisi AD, İZMİR
[3]Sağlık Bakanlığı, İzmir Eğitim Hastanesi, Nöroloji AD, İZMİR

Abstract

A 53 year-old male with central nervous system (CNS) located gumma was reported in a tertiary syphilis case. After related laboratory tests were performed, MRI investigation revealed diffuse cerebral atrophy and hypertense lesions around the periventricular region in the T2 section. In addition, neurological, laboratory and oral findings with differential diagnosis of neurosyphilis were discussed in the presented case report.

Keywords: neurosyphilis, cerebral atrophy, gumma

Özet

53 yaşındaki erkek hastada tersiyer sifiliz vakası ve santral sinir sisteminde (SSS) lokalize gom oluşumu rapor edildi. İlgili laboratuvar testlerinden sonra yapılan MRI incelemesinde yaygın serebral atrofi ve T2 kesitinde periventriküler bölge etrafında hipertens lezyonlar görüldü. Bu olgu sunumunda, nörosifilizin nörolojik, laboratuvar ve oral bulgularıyla birlikte ayırıcı tanısı da tartışıldı.

Anahtar sözcükler: *nörosifiliz, serebral atrofi, gom*

Introduction

Neurosyphilis presents in 5% of untreated syphilitic cases.[1-3] Asymptomatic neurosyphilis, syphilitic meningitis, meningovascular syphilis, gummatous neurosyphilis and parenchymatous syphilis are types of neurosyphilis. The clinical manifestations of parenchymatous syphilis can be divided into two groups as dementia paralytica and tabes dorsalis.[1] Dementia paralytica is a chronic progressive meningoencephalitis. There is deterioration in cognitive functioning and as the disease progresses symptoms like loss of strength, pupillary abnormalities, dysarthria and tremor of tongue and hands can be seen.[2] Tabes dorsalis begins with pain in lower extremities and it progresses to loss of proprioceptive sense.[3] Our aim was to report a CNS located gumma and oral findings in a rare tertiary syphilis case.

Case Report

In December 2002, a 53 year-old male patient presented with 9-month of partial memory loss and slowness in motion. His psychotic condition had begun one year ago. He was seen at the Department of Neurology in Ministry of Health Izmir Education Hospital and was hospitalized to examine the etiology of his dementia. The patient had irritability, poor concentration, mental confusion and depression. His reflexes were normal. He showed symptoms of abnormal gait, incontinence,

Kabul Tarihi: 10.12.2004

dementia and weakness. Clinical examination showed numbness of lower extremities, muscle contractions in right hands were uncoordinated. Hematological tests, chemistry profile, electrocardiography (ECG) and chest radiograph, thyroid function tests, folic acid and B_{12} level of the patient were all normal. The patient was HIV-negative. Brucellosis haemagglutination test was also negative. Abdominal ultrasound graphy was normal. The results of cerebrospinal fluid examination were as follows: protein level 105 mg/dl, glucose 50 mg/dl, chlorine 137 mEq/l, no cells (Normal values are 15-45 mg/dl for protein, 45-70 mg/dl for glucose, 110-128 mEq/l for chlorine). Serum and cerebrospinal fluid (CSF) rapid-plasma-reagin (RPR) (+), serum treponemma pallidum haemagglutination (TPHA) (+) (1/2560).

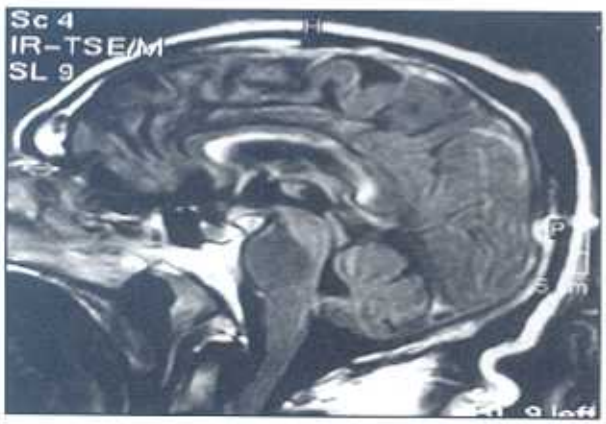

Figure 1. Diffuse cerebral atrophy.

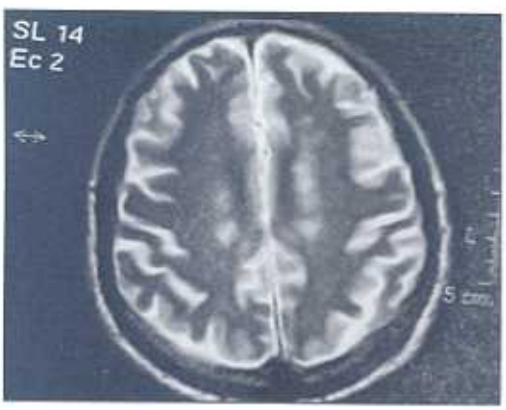

Figure 2. Hypertense lesions around the periventricular region in the T2 section.

Electroencephalography (EEG): Mild organization disorder. Cranial Magnetic resonance imaging (MRI): Cranial MRI scan revealed diffuse cerebral atrophy (Figure 1) and hypertense lesions around the periventricular region in the T2 section (Figure 2).

With all these findings, the patient was diagnosed as neurosyphilis. For the examination of oral tissues, the patient was referred to Department of Oral Diagnosis and Radiology, School of Dentistry, Ege University. No gumma was observed in clinical examination. Patient's oral hygiene was poor and atrophic glossitis was present (Figure 3). The patient was given 2.4 million units of aqueous penicillin IV (Pronapen (Pfizer), 800.000 units, 3x1) for 14 days owing to CNS involvement. He was also given 2 400 000 units benzathine penicillin (Penadur LA, Wyeth) 2 times in 2 weeks. Owing to cerebral involvement, no remission was observed in clinical and laboratory findings in monthly controls. The patient is still being followed up.

Figure 3. Atrophic areas on ventral surfaces and on the tip of tongue.

Discussion

Neurosyphilis can imitate schizophrenia, paranoid disorder or degenerative dementia.[4] It may present hysteric manners or delirium which were also observed in our patient. In laboratory examination the TPHA test was (+) for the patient and MRI examination showed cerebral atrophy, T2 hyperintensity related to gumma, brightness in

leptomeninges and infarct sites due to vascular involvement.[5] The cerebral atrophy was the most effective reason for the poor prognosis of our patient. Memory impairments and cognitive decline due to frontal and temporal lobe involvement occur early in neurosyphilis.[6] Common MRI findings are dilating ventricles and increased signal or atrophy of medial temporal lobes. If MRI shows cerebral atrophy it indicates a poor prognosis[7]. These patients have problems in social functions and they experience personality changes and generalized dementia.[1] Although most of the syphilitic cases are HIV (+), our patient was HIV (-).

References

1. Britton LJ, Joyner BE, Ewart AH. Neurosyphilis: not to be forgotten. *Intern Med J* 2004; 34: 299-300.
2. Schiff E, Lindeberg M. Neurosyphilis. *South Med J* 2002; 95: 1083-1087.
3. Lauria G, Erbatta A, Pareyson A, et al. Parenchymatous Neurosyphilis. *Neurol Sci* 2001; 22: 281-282.
4. Mochizuki H, Kamakura K, Kanzaki M, Nishii T, Matsuo H, Motoyoshi K. Somatosensory evoked potential in Neurosyphilis. *J Neurol* 2002; 249: 1220-1223.
5. Marra CM. Neurosyphilis. *Curr Neurol Neurosci Rep* 2004; 4: 435-440.
6. Lair L, Naidech AM. Modern neuropsychiatric presentation of neurosyphilis. *Neurology* 2004; 63: 1331-1333.
7. Saik S, Kraus JE, McDonald A, Mann SG, Sheitman BB. Neurosyphilis in newly admitted psychiatric patients: three case reports. *J Clin Psychiatry* 2004; 65: 919-921.

Yazışma Adresi:

Doç. Dr. Nesrin DUNDAR

Ege Üniversitesi,
Dişhekimliği Fakültesi,
Oral Diagnoz ve Radyoloji AD,
35100 – Bornova / İZMİR
Tel : (232) 388 10 81
Faks : (232) 388 03 25
E-posta : nesrinergul@yahoo.com