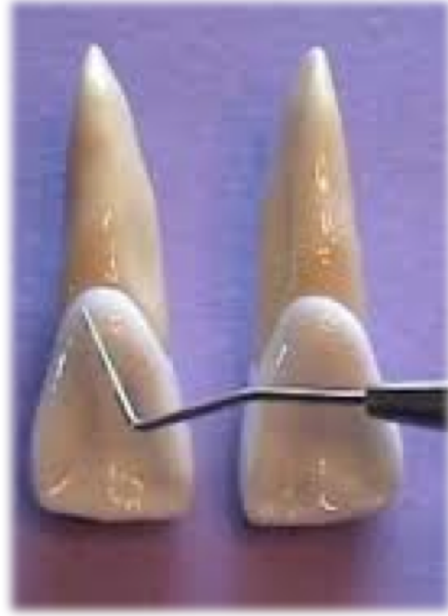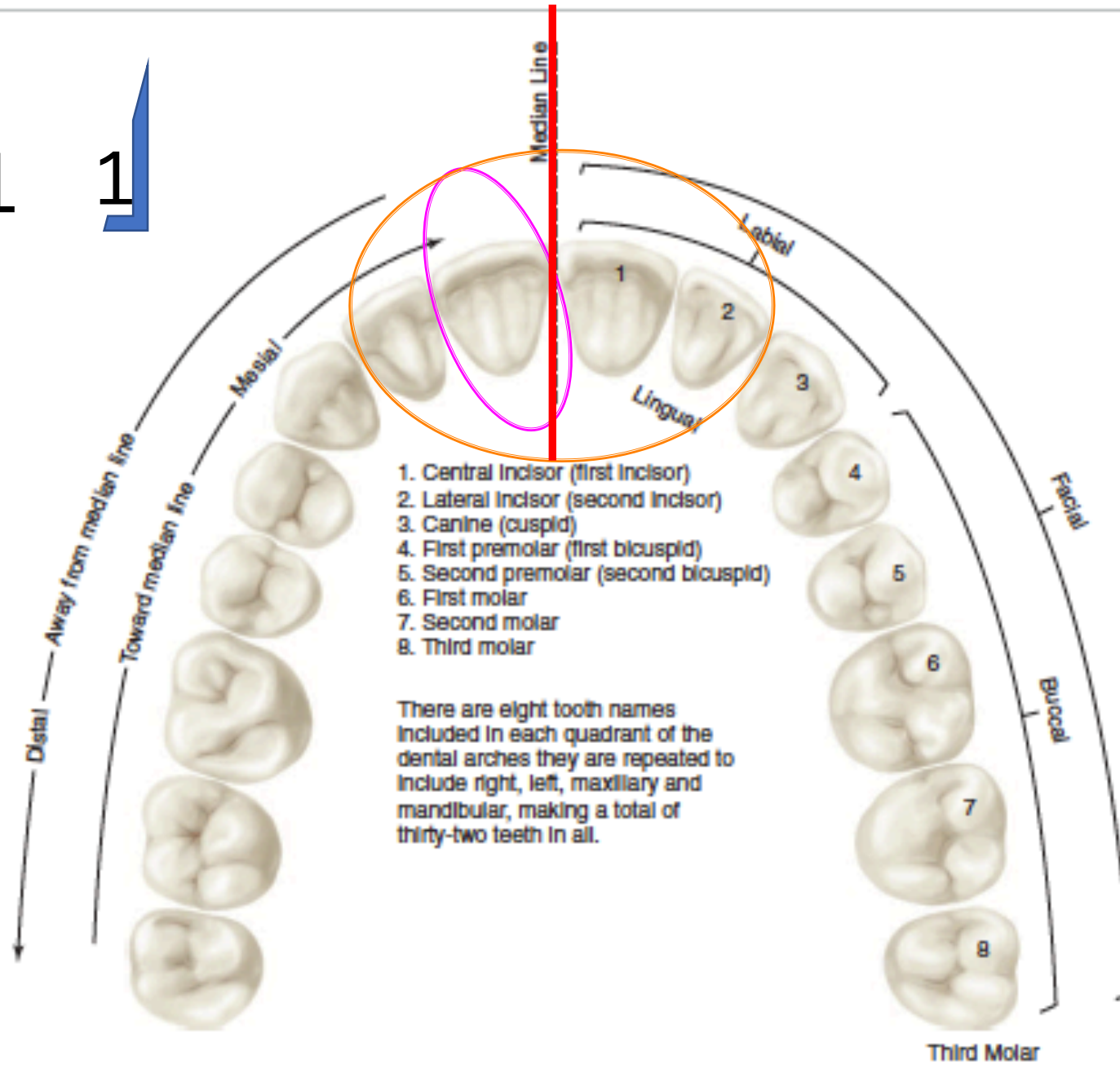


ÜST SANTRAL KESİCİ DİŞ



Dr. Gülcan Coşkun Akar

11

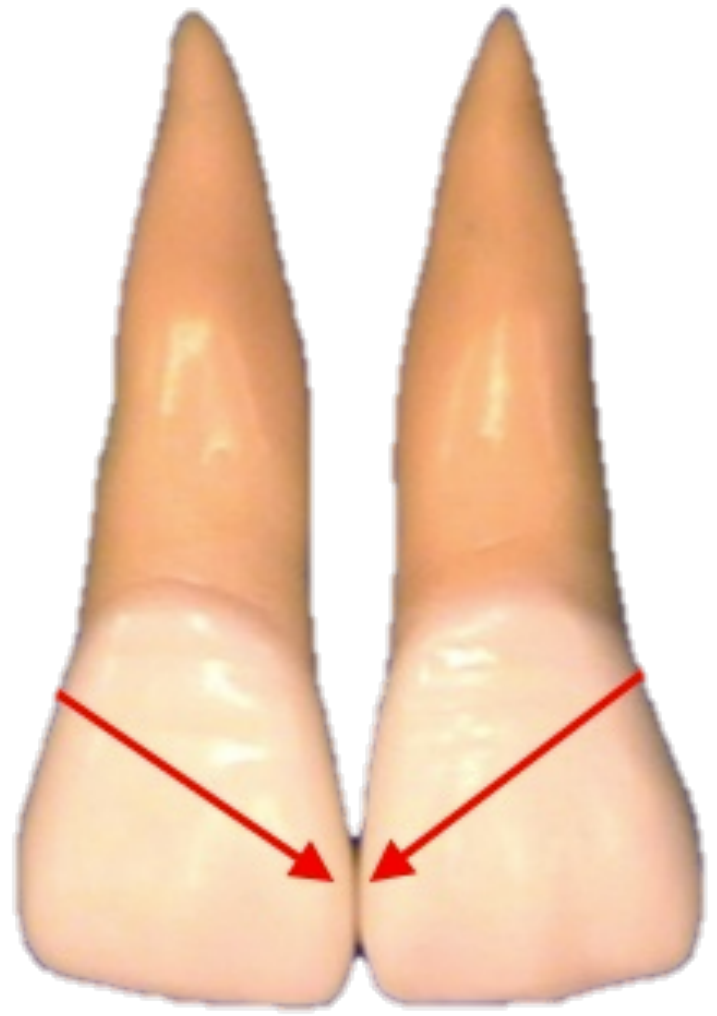
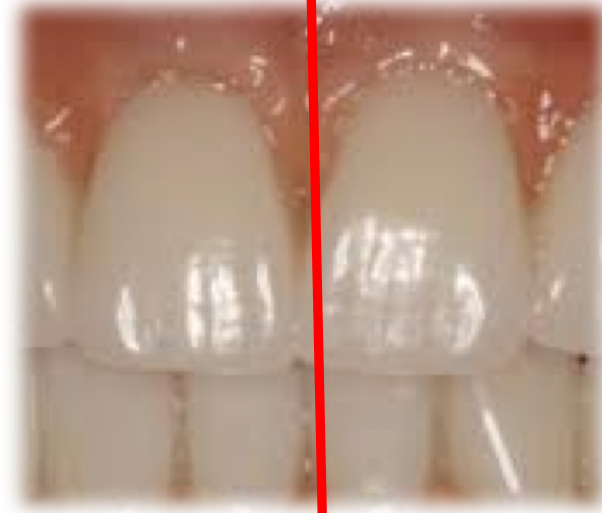
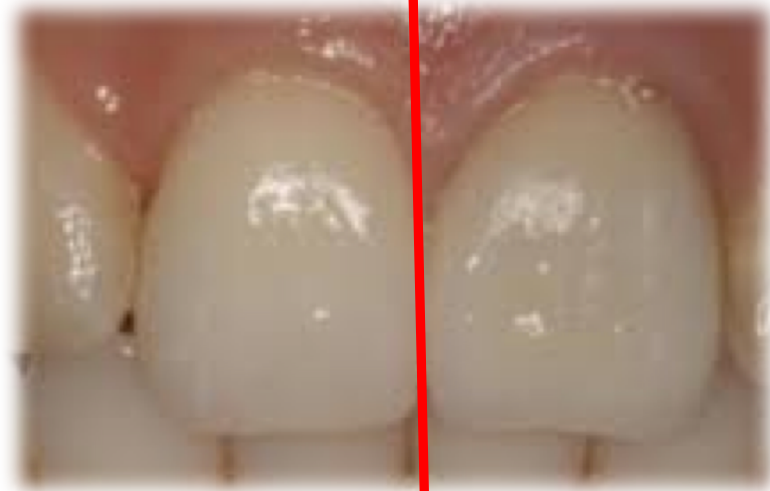
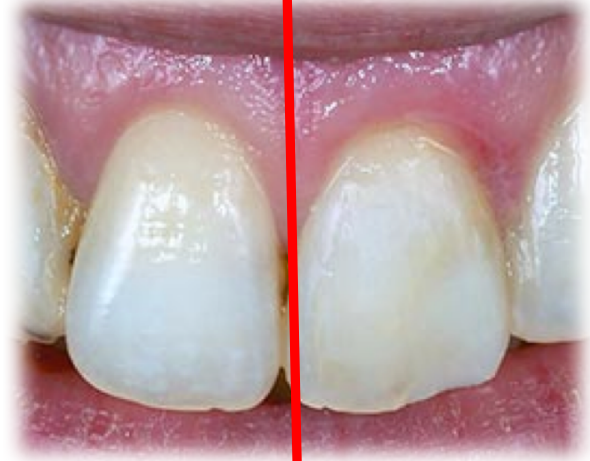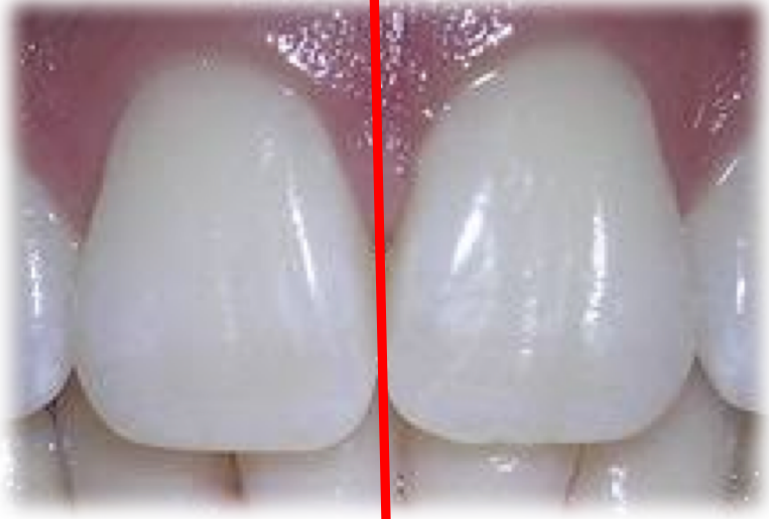Third Molar

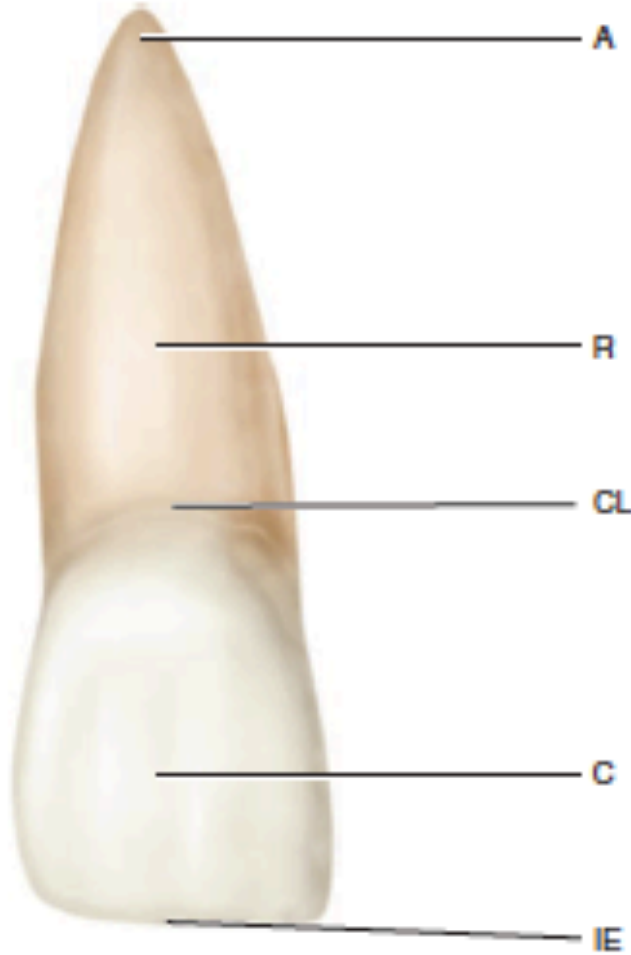
TABLE 1-1 Measurements of the Teeth: Specifications for Drawing and Carving Teeth of Average Size*

	LENGTH OF CROWN	LENGTH OF ROOT	MESIODISTAL DIAMETER OF CROWN [†]	MESIODISTAL DIAMETER OF CROWN AT CERVIX	LABIO- OR BUCCOLINGUAL DIAMETER OF CROWN	LABIO- OR BUCCOLINGUAL DIAMETER OF CROWN AT CERVIX	CURVATURE OF CERVICAL LINE—MESIAL	CURVATURE OF CERVICAL LINE—DISTAL
Maxillary Teeth								
Central incisor	10.5	13.0	8.5	7.0	7.0	6.0	3.5	2.5
Lateral incisor	9.0	13.0	6.5	5.0	6.0	5.0	3.0	2.0
Canine	10.0	17.0	7.5	5.5	8.0	7.0	2.5	1.5
First premolar	8.5	14.0	7.0	5.0	9.0	8.0	1.0	0.0
Second premolar	8.5	14.0	7.0	5.0	9.0	8.0	1.0	0.0
First molar	7.5	B L 12 13	10.0	8.0	11.0	10.0	1.0	0.0
Second molar	7.0	B L 11 12	9.0	7.0	11.0	10.0	1.0	0.0
Third molar	6.5	11.0	8.5	6.5	10.0	9.5	1.0	0.0
Mandibular Teeth								
Central incisor	9.0 [‡]	12.5	5.0	3.5	6.0	5.3	3.0	2.0
Lateral incisor	9.5 [‡]	14.0	5.5	4.0	6.5	5.8	3.0	2.0
Canine	11.0	16.0	7.0	5.5	7.5	7.0	2.5	1.0
First premolar	8.5	14.0	7.0	5.0	7.5	6.5	1.0	0.0
Second premolar	8.0	14.5	7.0	5.0	8.0	7.0	1.0	0.0
First molar	7.5	14.0	11.0	9.0	10.5	9.0	1.0	0.0
Second molar	7.0	13.0	10.5	8.0	10.0	9.0	1.0	0.0
Third molar	7.0	11.0	10.0	7.5	9.5	9.0	1.0	0.0

Kalsifikasyonun ilk kanıtı	3-4 ay
Minenin tamamlanması	4-5 yaş
Erüpsiyon	7-8 yaş
Kök tamamlanması	10 yaş



	Kron serviko-insizal uzunluđu	Kök Uzunluđu	Kronun mezyo-distal çapı	Kronun boyun kısmındaki mezyo-distal çapı	Kronun labio-lingual yada bukkolingual çapı	Kronun boyun kısmındaki labiolingual yada bukkolingual çapı	Mezyal yüzdeki servikal çizgi derinliđi	Distal yüzdeki servikal çizgi derinliđi
Modalajda önerilen boyutlar	10,5 mm	13 mm	8,5 mm	7,0 mm	7,0 mm	6,0 mm	3,5 mm	2,5 mm



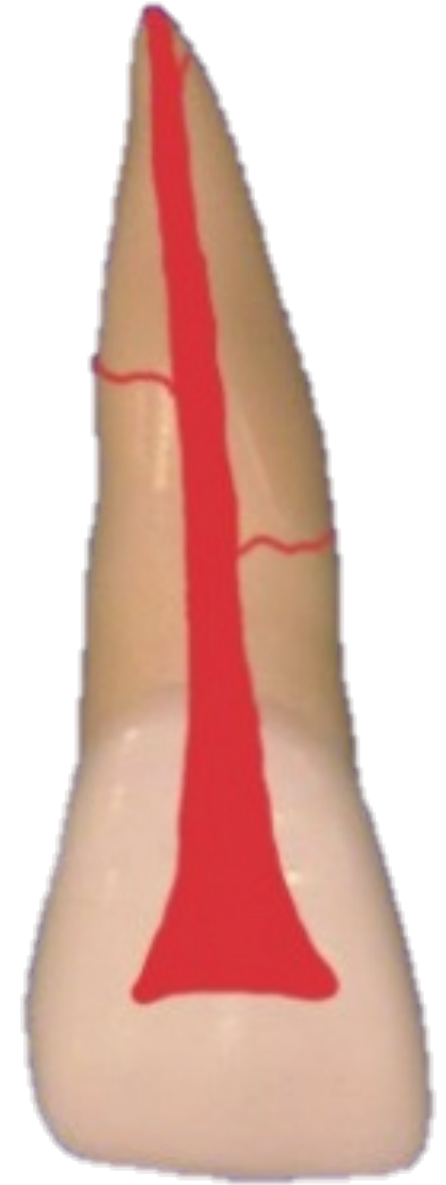Kök Apeksi

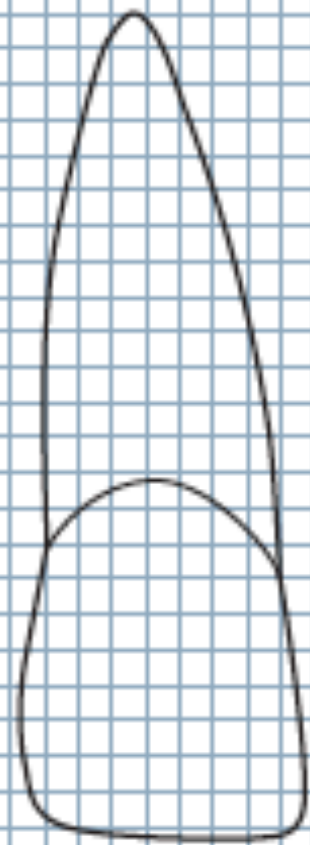
Kök

Servikal Çizgi

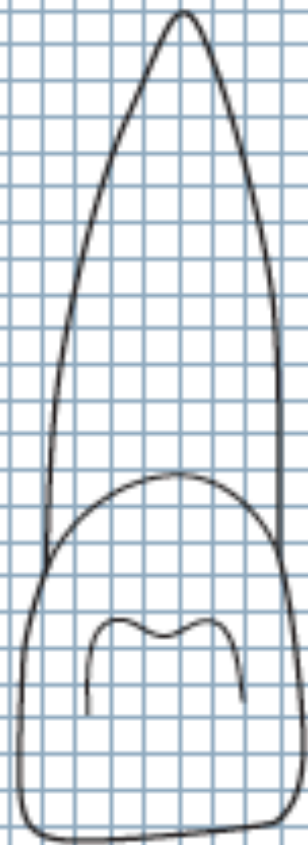
Kron

İnsizal Kenar

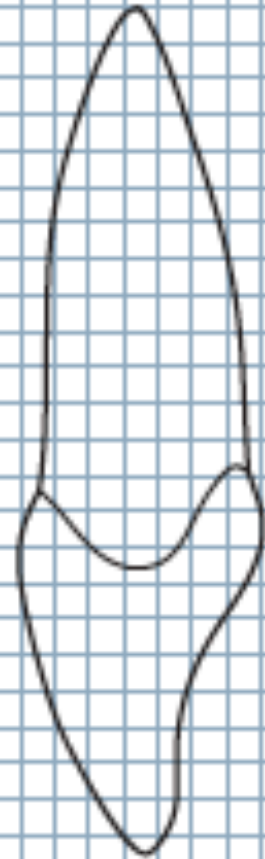



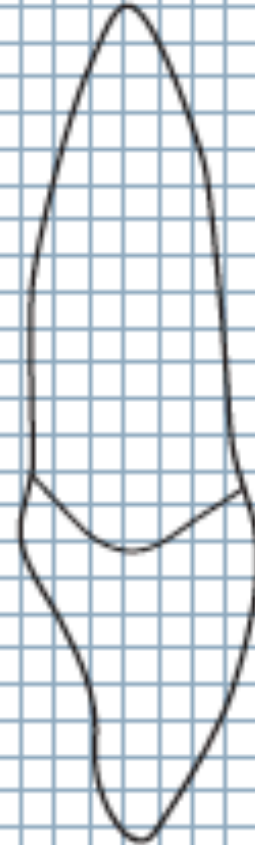
Labial



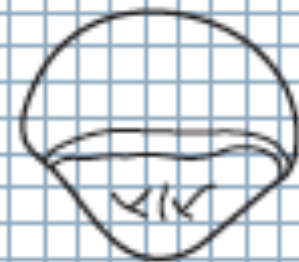Lingual



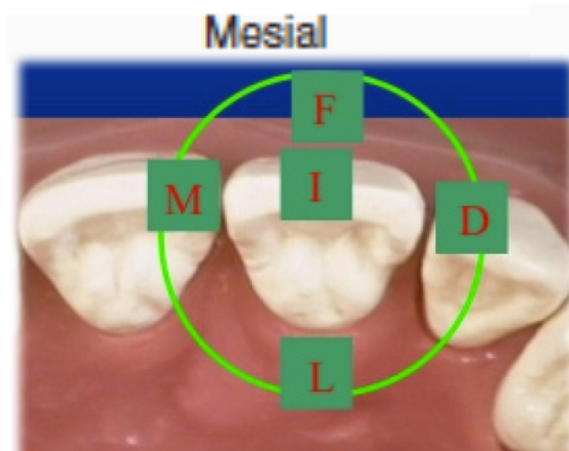
Mesial



Distal

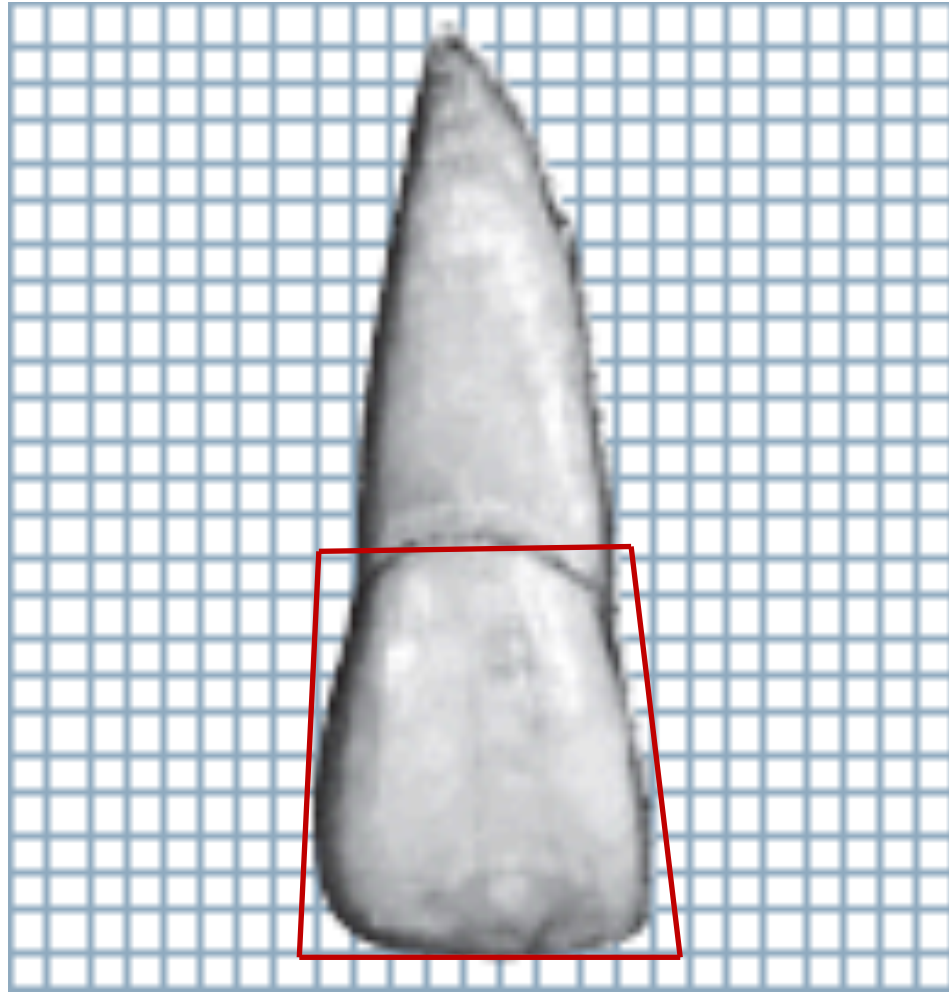
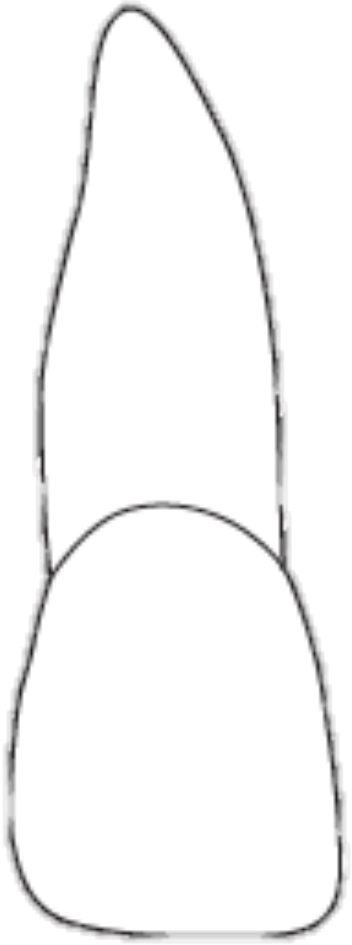

Incisal

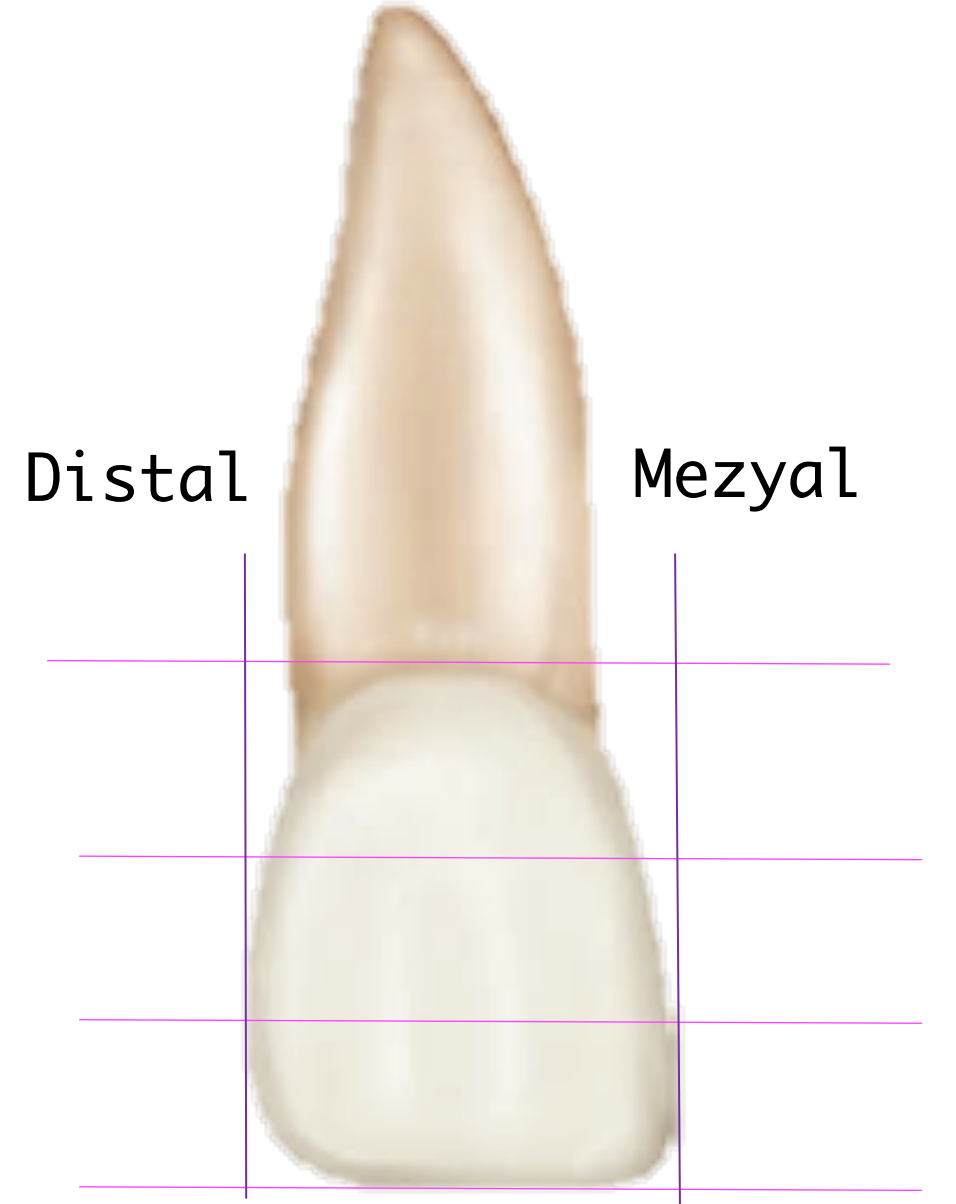
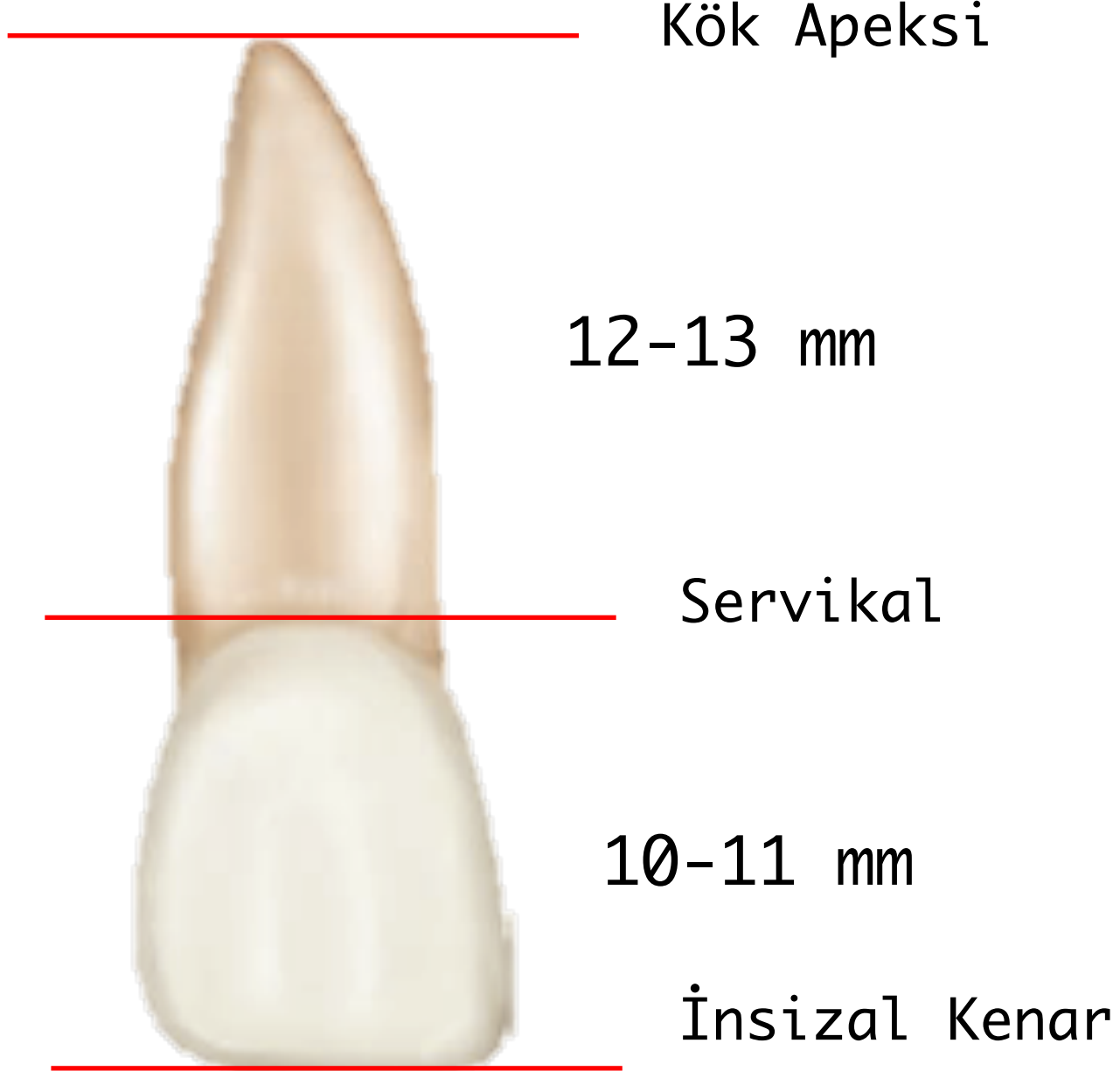


LABIAL YÜZ

Trapezoidal



LABIAL YÜZ



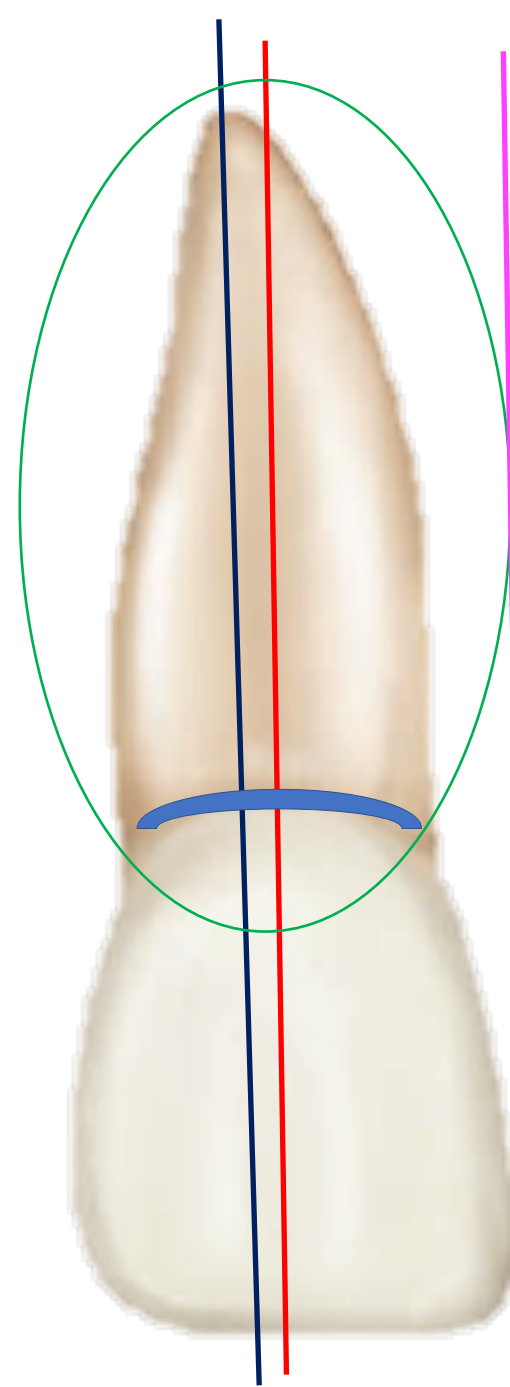
LABIAL YÜZ

Mine yüzeyi düzgün

Labial yüz hatları genellikle dış bükey
(konveks)

Orta ve insizal üçlü servikal üçlü
alanından daha düz hatlı

Simetriğe yakın bir görünüm



Kök konik
Kör apeks

Mezyal ve
distalde, bukkal
ve palatinalden
daha ince

LABIAL YÜZ

Servikal çizgi eğimi köke doğru

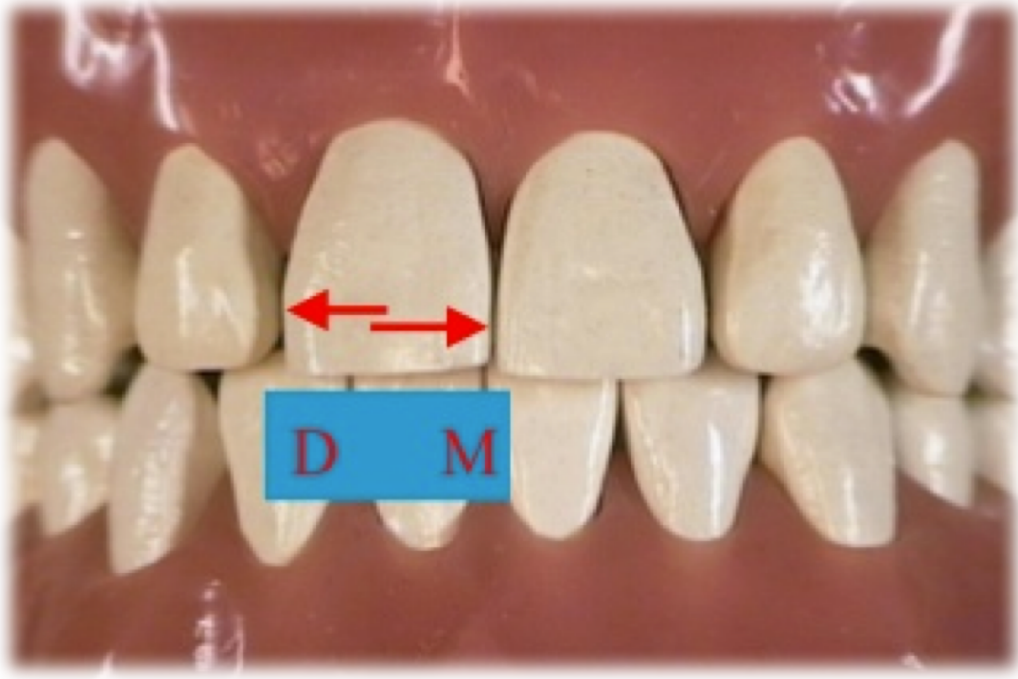
Distal alan kavisli
Distal insizal açı yuvarlak

İnsizal kenar düze yakın

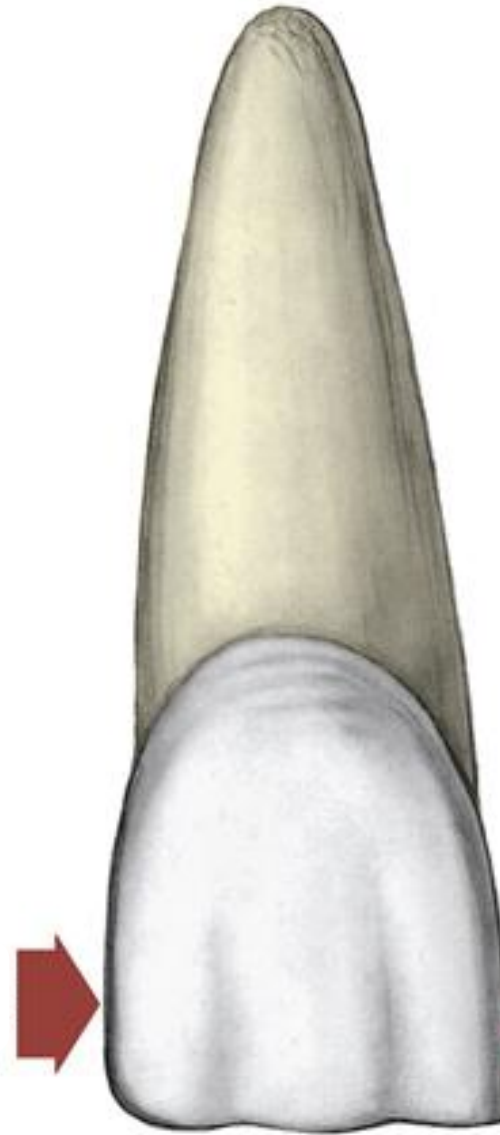


Mezyal alan düz hatlı

Mezyal insizal açı keskin

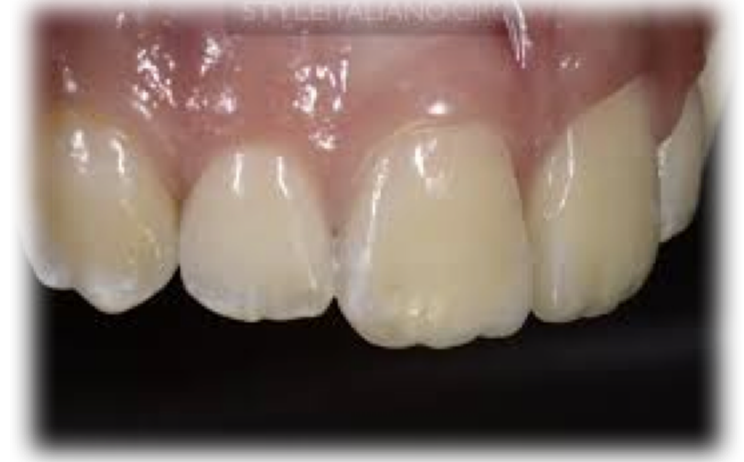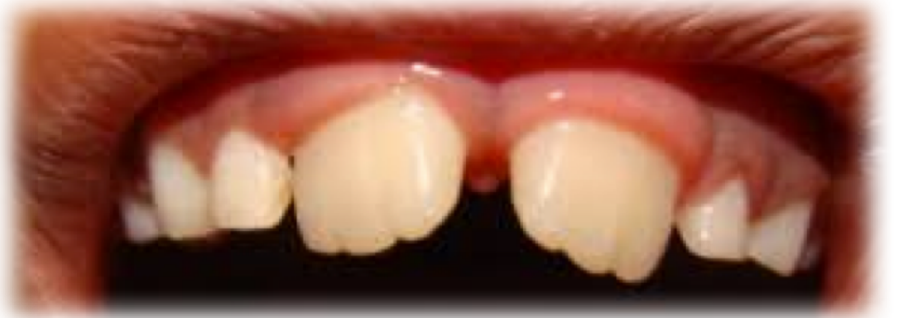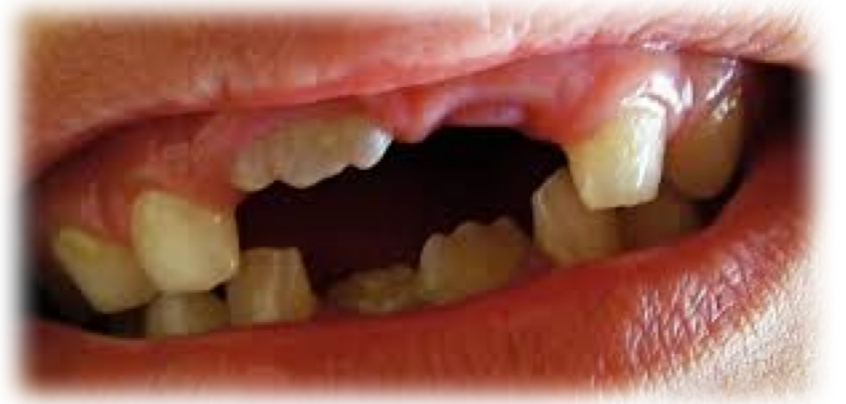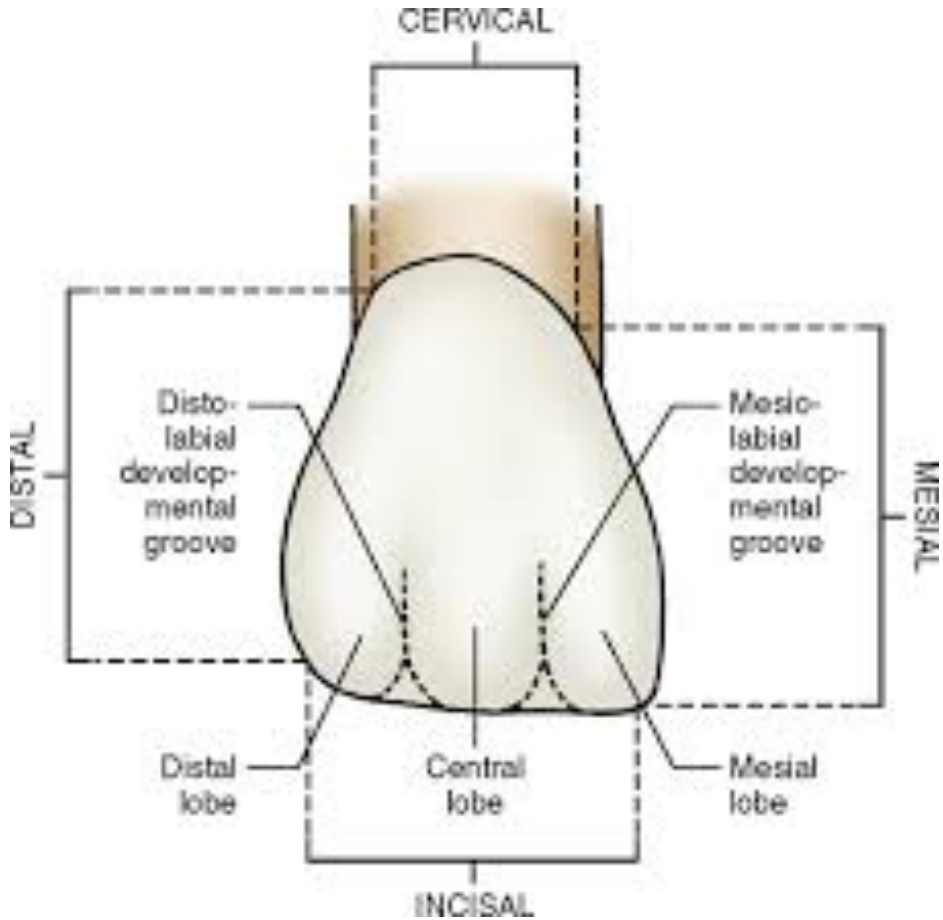


Distal deęim alanı
Orta üçlü ile insizal üçlünün birleşiminde




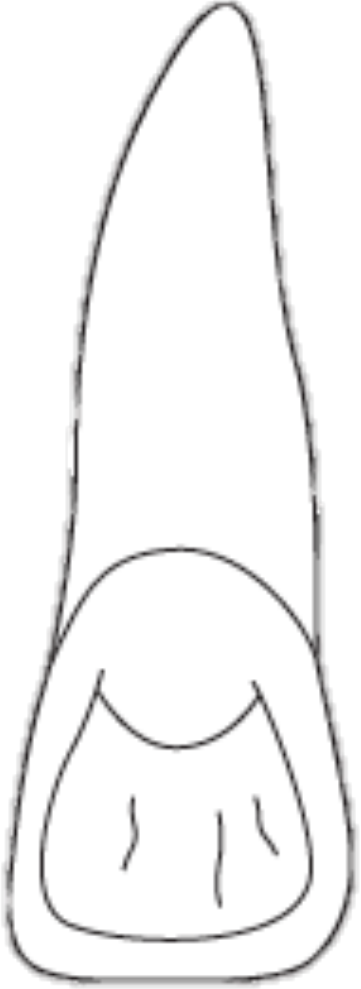
Mezyal deęim alanı
İnsizal üçlüde

Diş yeni sürdüğünde veya aşınma az olduğunda insizal kısımda mamelonlar izlenebilir. Labial yüzdeki gelişim olukları yüzeyi üç parçaya böler. Ortada yer alan kısım en belirgin olandır.

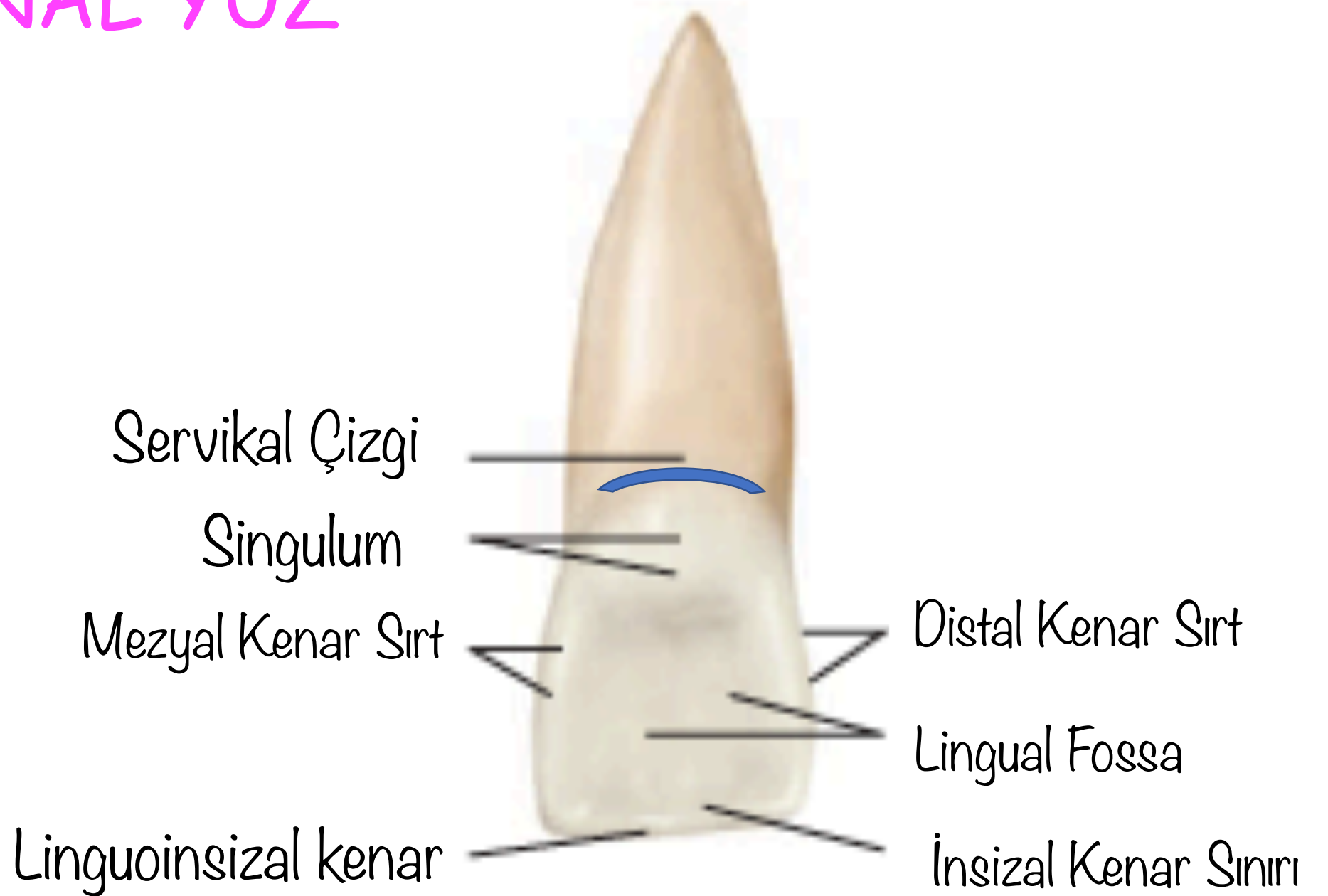


PALATINAL YÜZ

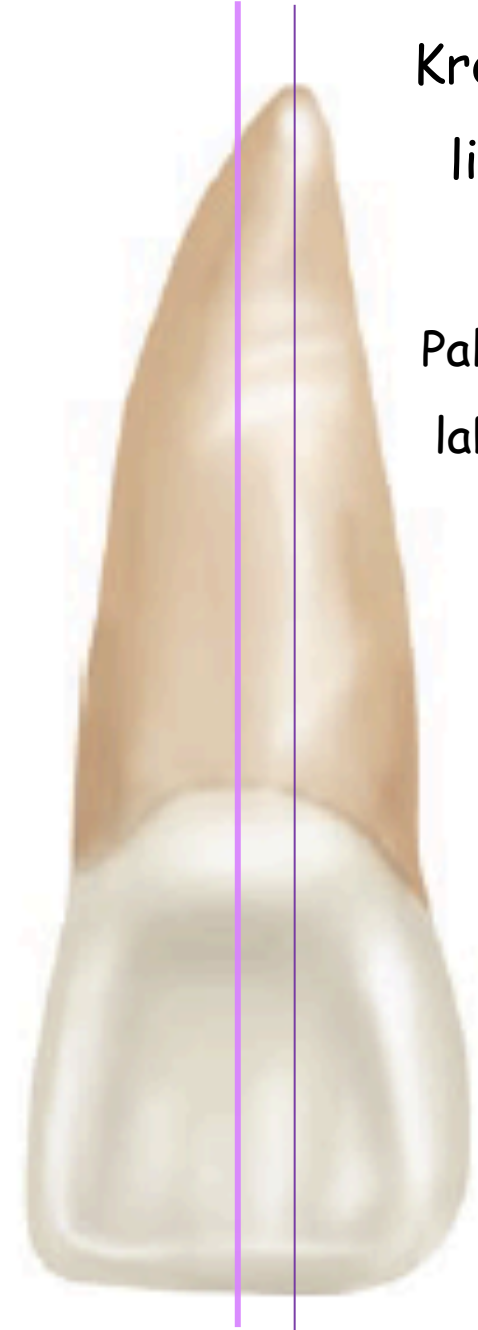
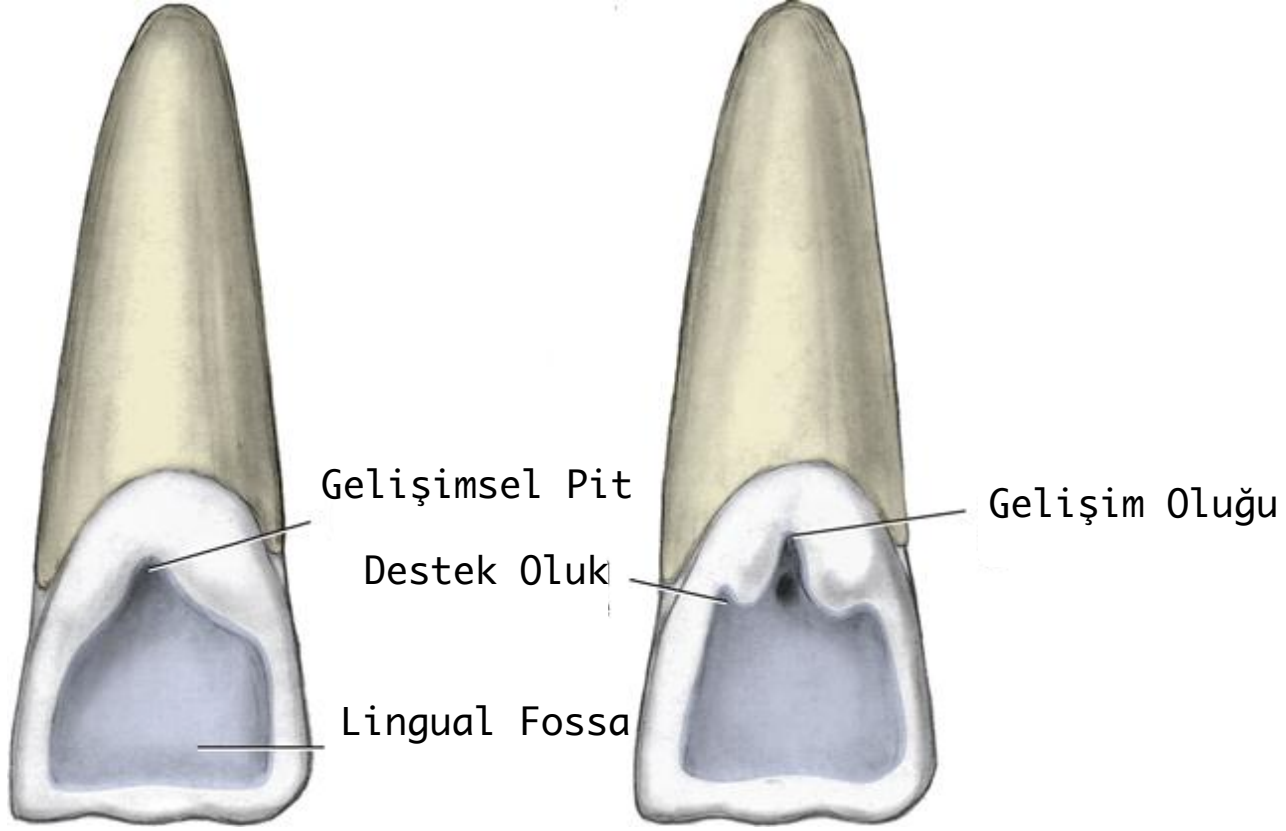
Trapezoidal



PALATİNAL YÜZ



PALATINAL YÜZ

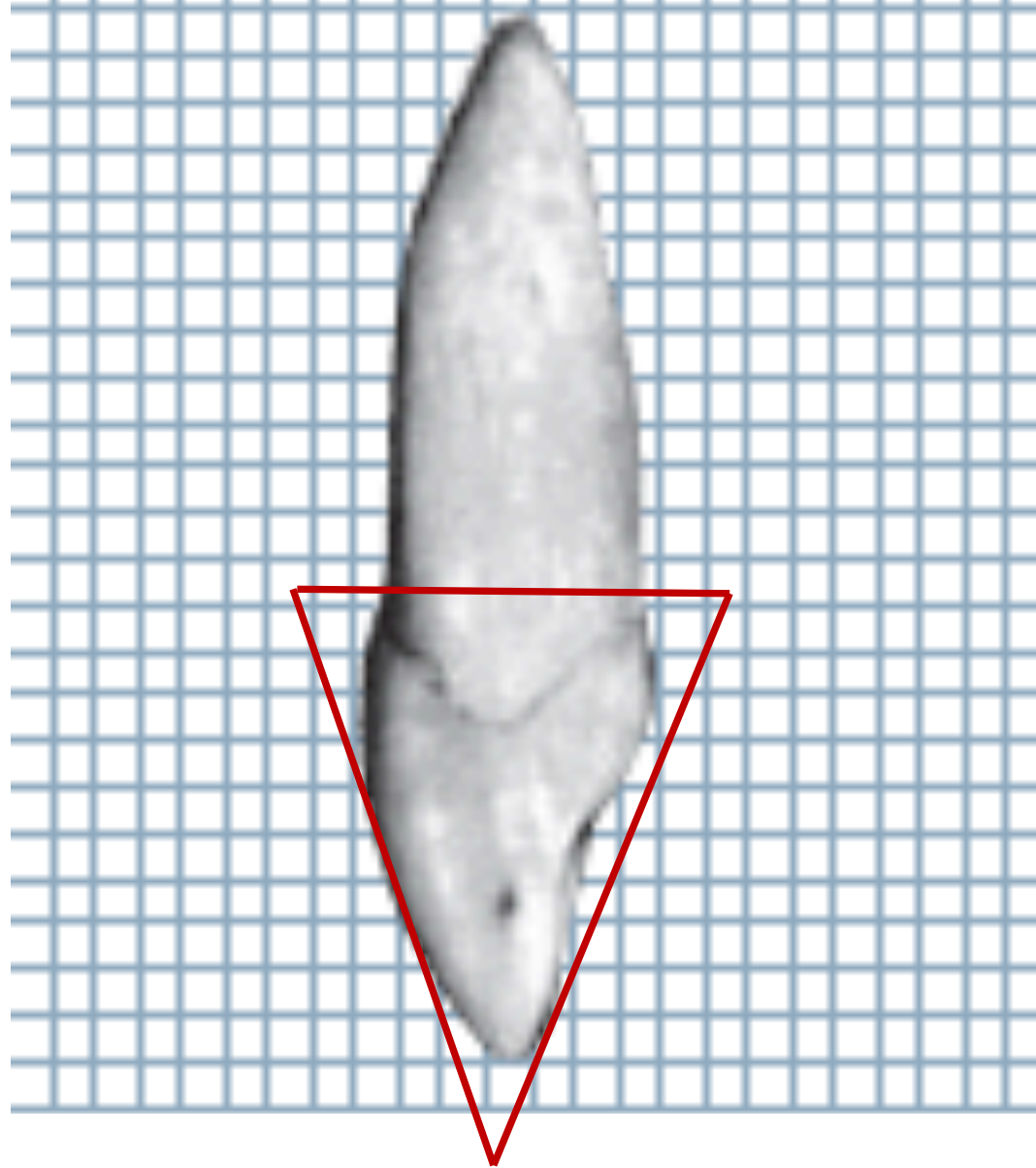
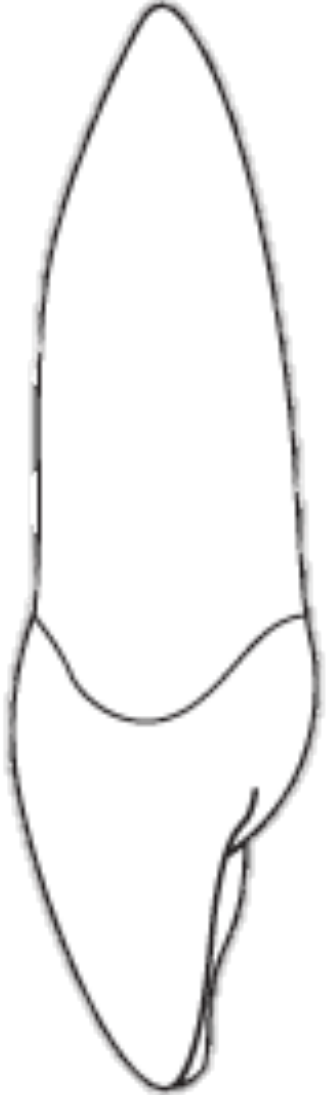

Kron ve kök hafif
linguale devrik

Palatinal kök yüzeyi
labial yüzden daha
dar

MEZYAL YÜZ

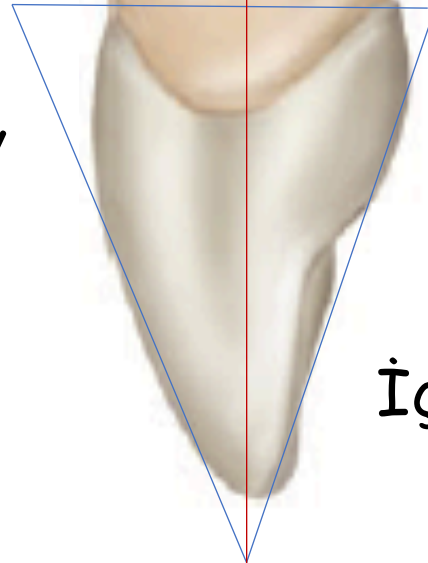
Üçgen



MEZYAL YÜZ

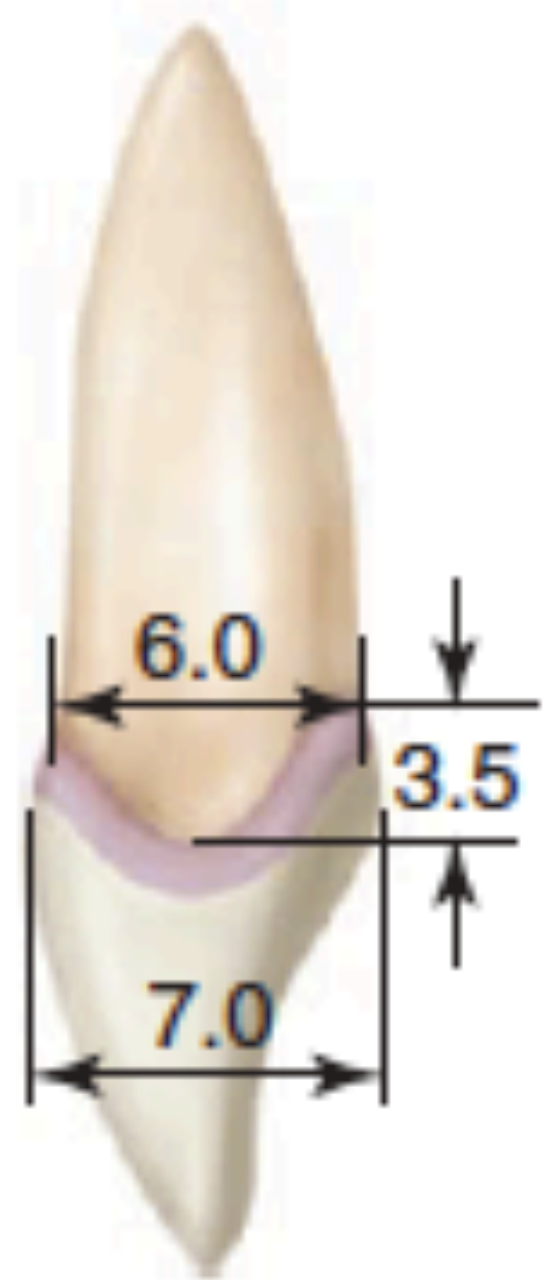
Kron apeksi kök
apeksi ve servikal
çizginin en derin
noktası aynı
düzlemededir.

Dış bükey

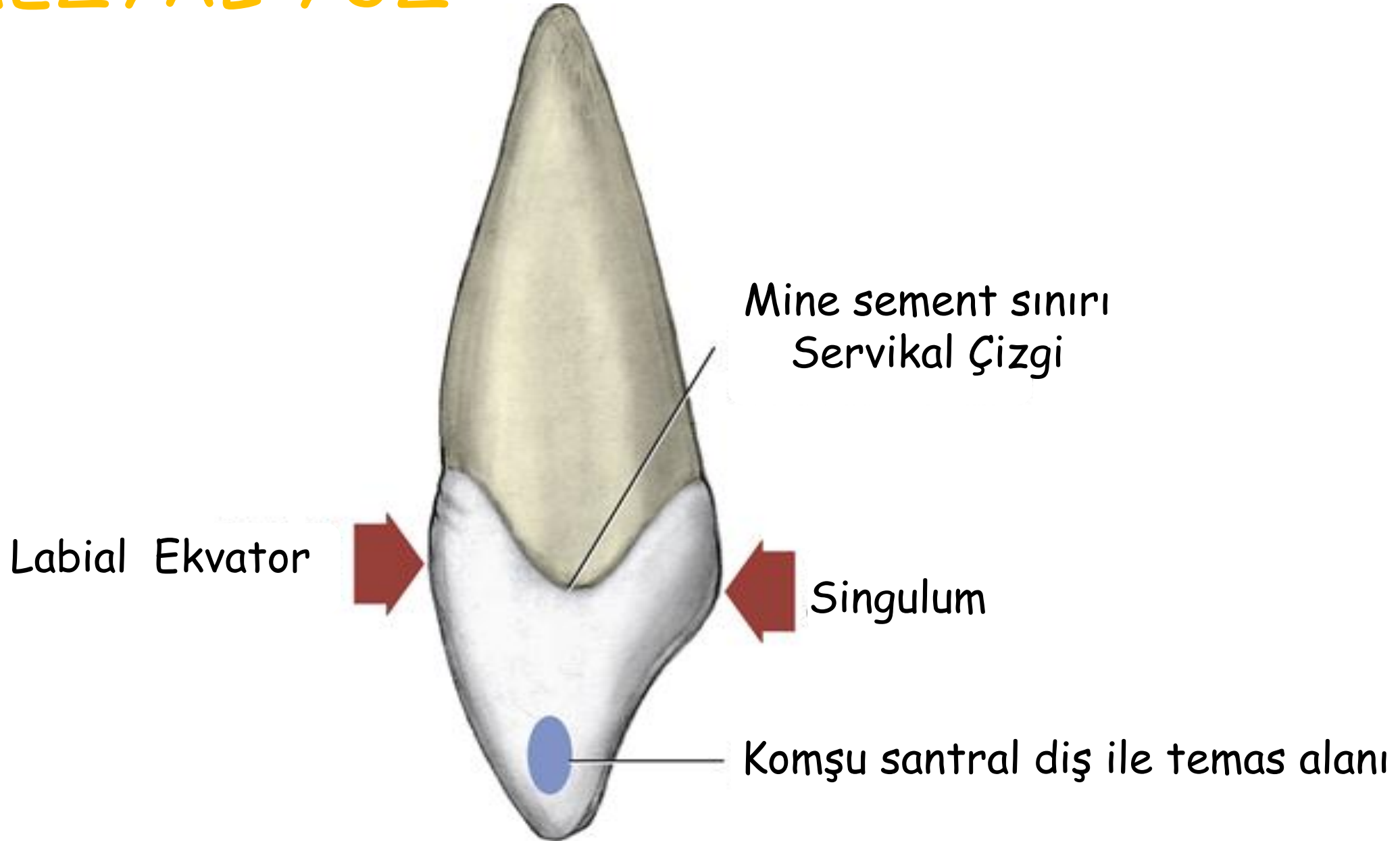


Dış bükey

İç bükey

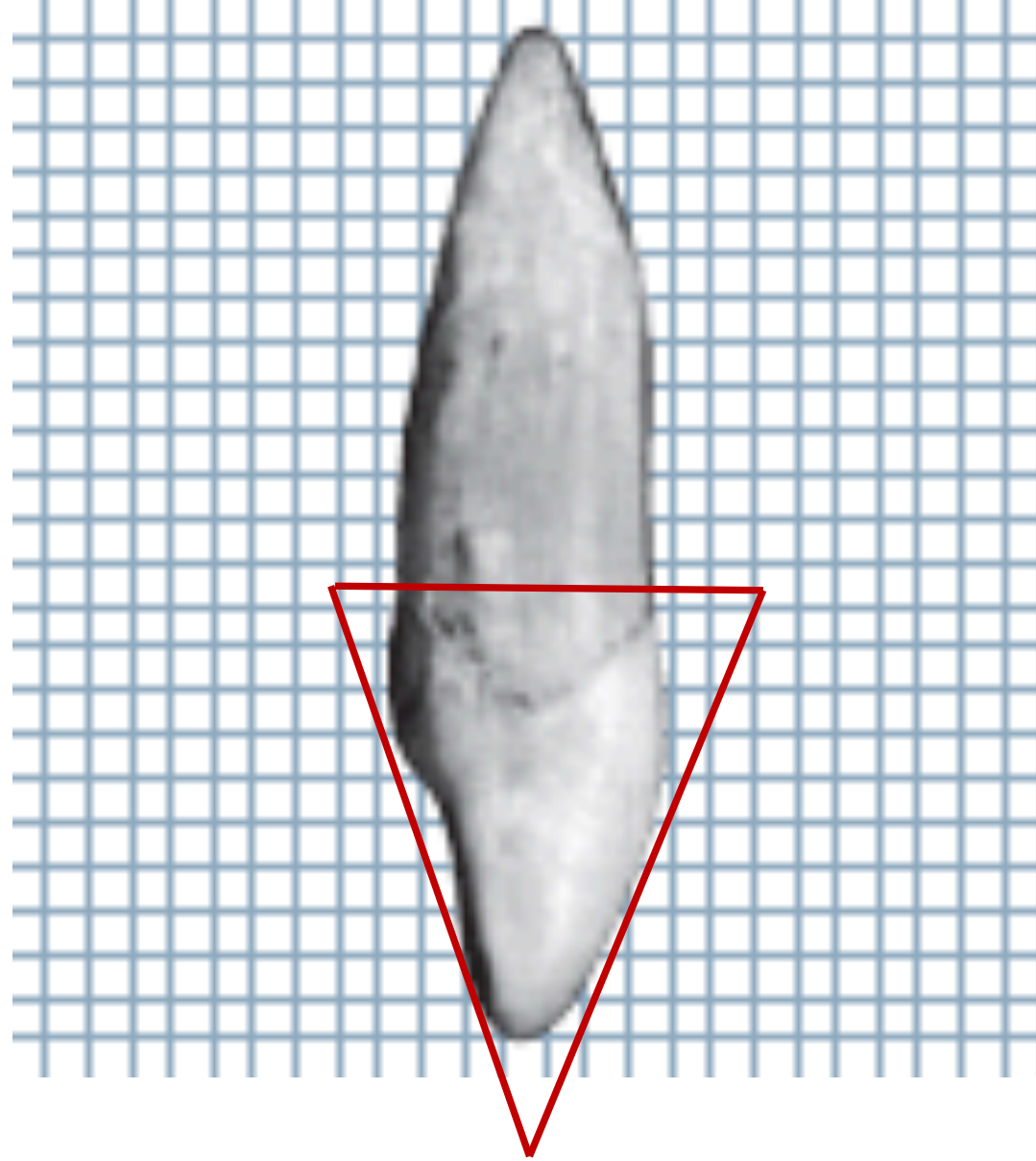


MEZYAL YÜZ

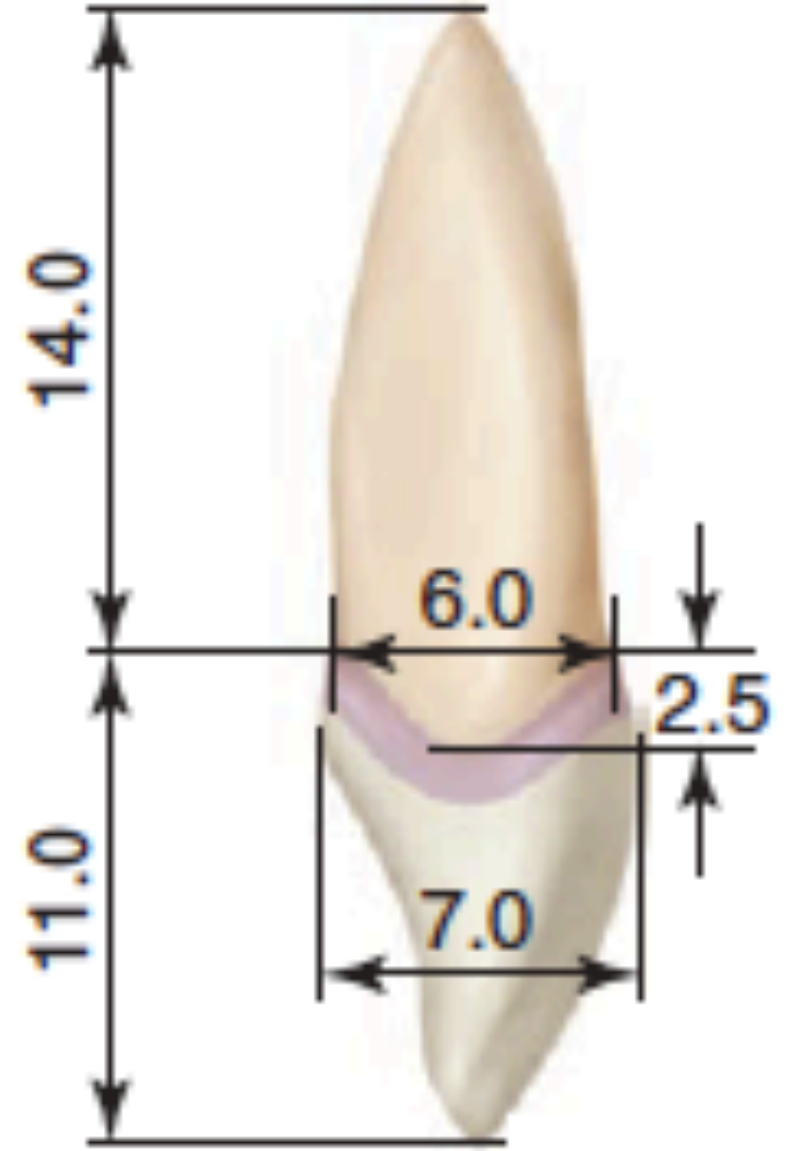
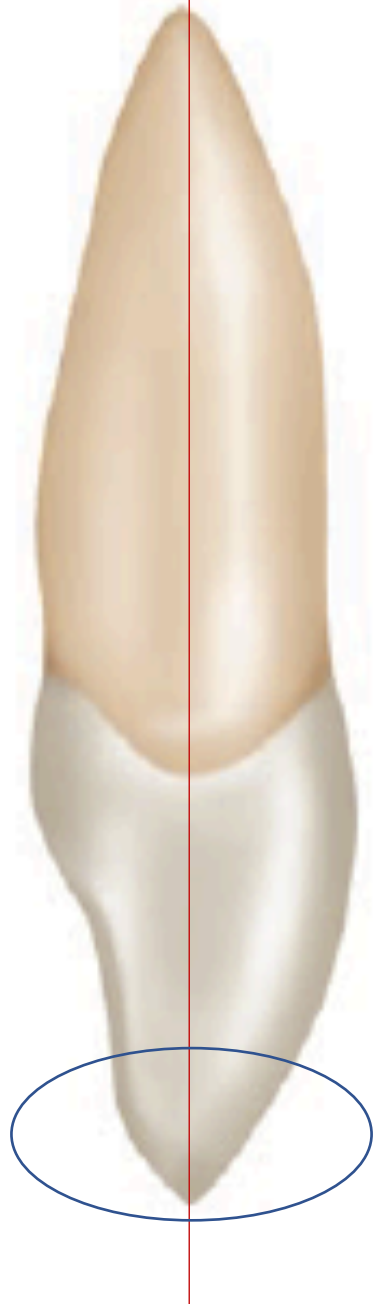

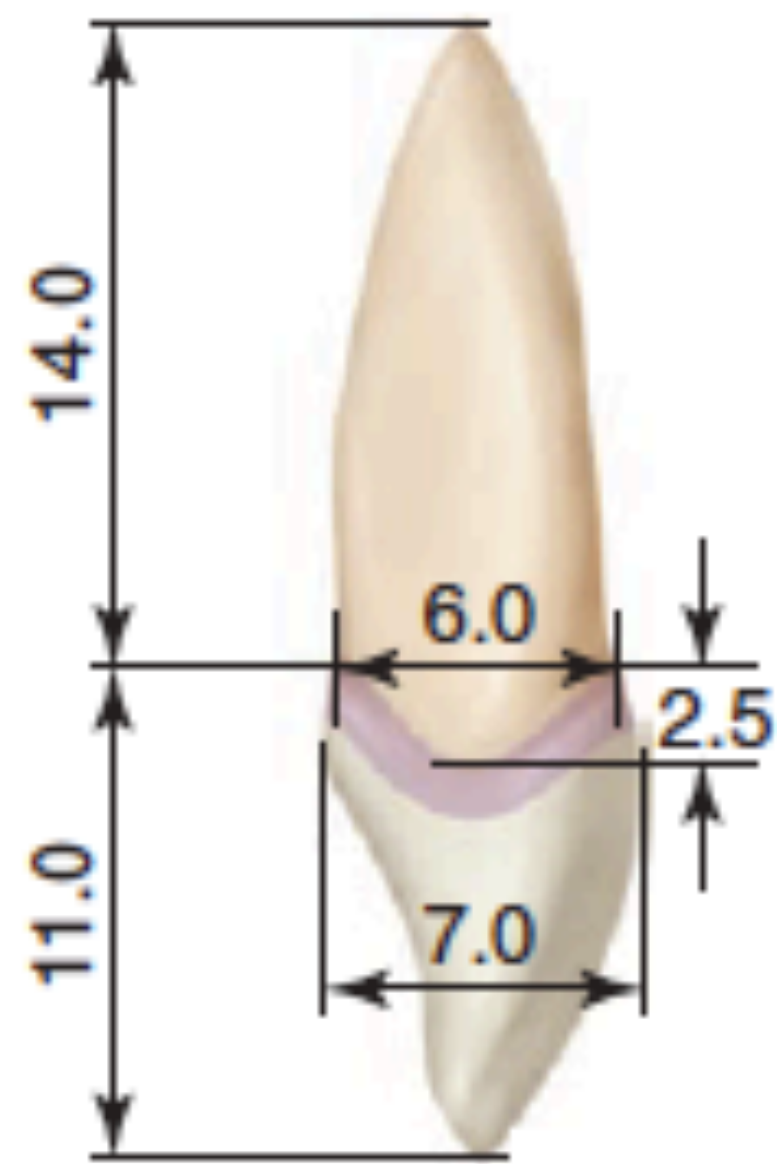
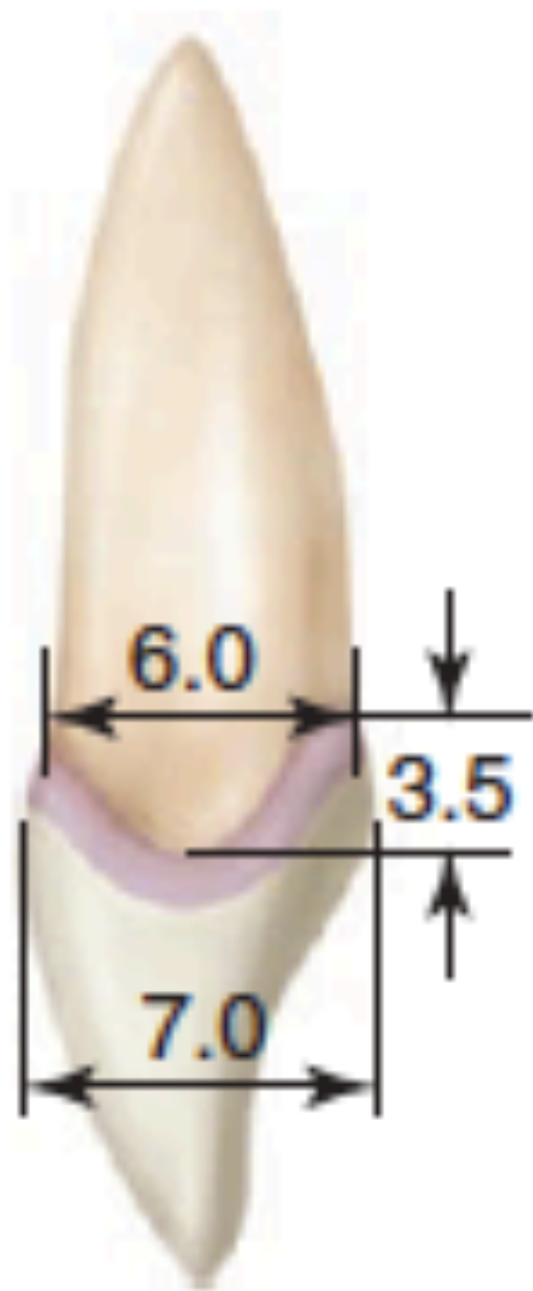DİSTAL YÜZ

Üçgen



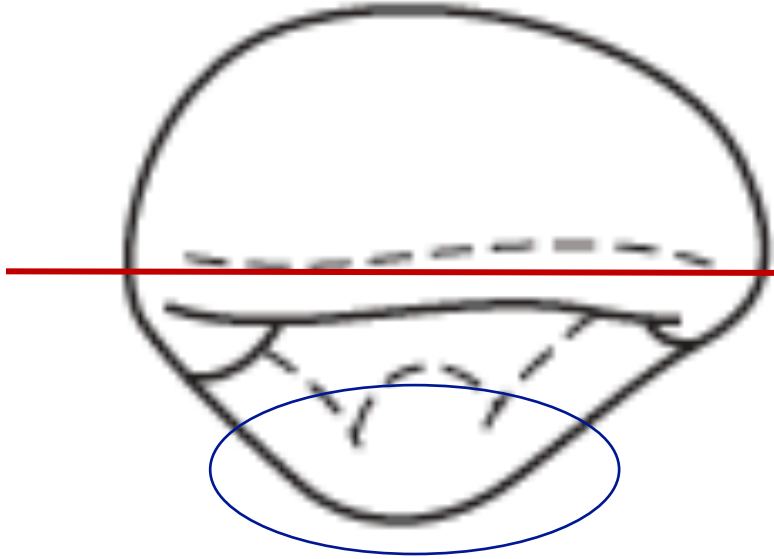
DİSTAL YÜZ



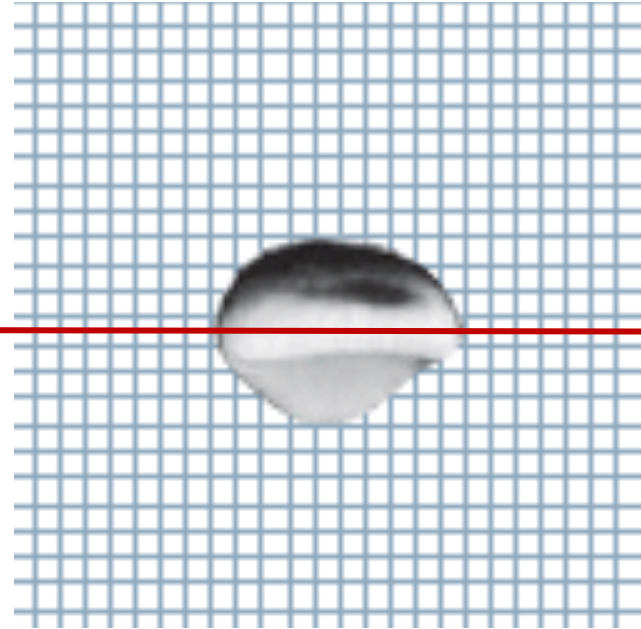


İNSİZAL YÜZ

Labial yüz insizal
üçlüye kadar düz
şekillenmiş olarak
görülebilir.



Lingual yüzde singulum izlenebilir.



Kök apeksi görülmez.

Labial yüzde servikal
kısm dış bükey
şekillenir. Bu durum ark
formunun oluşmasına olanak
sağlar.



İNSİZAL YÜZ

